

**ORIGINAL RESEARCH**

# Laparoscopic Ventral Hernia repair; Comparison of TAPP versus IPOM

<sup>1</sup>Dr. Mario Victor Newton, <sup>2</sup>Amogh Kaushik

<sup>1</sup>Consultant Advanced Laparoscopic Surgeon, St. John's Medical College Hospital, Sarjapur Road, Bengaluru, Karnataka, India

<sup>2</sup>MBBS Final Year, St. John's Medical College, Sarjapur Road, Bengaluru, Karnataka, India

**Corresponding author**

Dr. Mario Victor Newton

Present affiliation: Department of General Surgery, KMCH Institute of Health Science & Research, Coimbatore, Tamil Nadu, India

Email: [mvnewton@gmail.com](mailto:mvnewton@gmail.com)

Received date: 28 January, 2024

Acceptance date: 20 February, 2024

**ABSTRACT**

**Introduction:** A comparison between Laparoscopic TAPP versus IPOM. Laparoscopic ventral hernia repair has many benefits compared to open surgical repair, however the associated costs in relatively simpler laparoscopic IPOM have made it unaffordable for many in the developing countries. Laparoscopic TAPP is technically demanding however affordable.

**Methods:** A retrospective comparison between laparoscopic IPOM and TAPP cases over 1 year, done by a single laparoscopic surgeon, in terms of operative outcomes and cost.

**Results:** 16 patients, 12 in IPOM and 4 in the TAPP group. The meshes used among Laparoscopic IPOM cases were Parietex™ Composite mesh in 11, Proceed™ Surgical Mesh in 1; among Laparoscopic TAPP cases Vypro II® Mesh in 3, and PROLENE® Polypropylene mesh in 1. There was no significant difference in the mean defect size, mesh size, operating time, and hospital stay duration. No intra-operative, post-operative complication or recurrence was noted in both the groups. A significant difference in the mean cost of mesh used between the two groups noted (490 USD versus 91 USD, P=0.001).

**Conclusion:** Laparoscopic TAPP fares better than IPOM in circumventing the issues of mesh coming in contact with the viscera as the mesh is placed in a separate pocket, less pain, no increase seen in complications or recurrence, with less cost of materials used making laparoscopic ventral hernia repair affordable for the lower socio economic status people too.

**Keywords:** Hernia, Abdominal Hernia, Incisional Hernia, Surgical Mesh, Laparoscopy, Laparoscopic Surgery

This is an open access journal, and articles are distributed under the terms of the Creative Commons Attribution- Non Commercial-Share Alike 4.0 License, which allows others to remix, tweak, and build upon the work non-commercially, as long as appropriate credit is given and the new creations are licensed under the identical terms.

**INTRODUCTION**

Each year United States spends 3.2 billion dollars in the operative management of 400000 ventral hernias<sup>(1)</sup>, there are various choices of mesh placed at different planes of the abdominal wall during surgery; the cost of mesh varies widely and may eclipse the proposed cost of surgery.<sup>(1)</sup> The mesh placed in the retro-muscular planes like sublay, underlay or preperitoneal gives good mechanical support based on Pascal's law.<sup>(2)</sup> The incidence of surgical site infection is 1% in laparoscopic repair compared to 10% in open repair.<sup>(2)</sup> In laparoscopic repair, American college of surgeons have found significant decrease in the surgical site infections (superficial & deep), wound disruption and prolonged hospital stay when compared to open hernia repair.<sup>(3)</sup> Also laparoscopic repair is beneficial in patient with co-morbidities, increased BMI, and multiple defects.<sup>(3)</sup> Among the laparoscopic repair methods, IPOM (Intra-peritoneal onlay mesh repair) is relatively simple and requires less technical expertise whereas TAPP

(Transabdominal Pre-peritoneal approach) requires some dissection, careful creation of pre-peritoneal plane otherwise leading to tears in the peritoneum. Hence IPOM is the most common repair done through laparoscopy, however owing to the cost of mesh, many times patient had to opt for open repair techniques. Also the contact of mesh with the bowel may increase the chances of adhesion, obstruction, mesh infection, enterocutaneous fistula.<sup>(4)</sup> In our study we have compared the surgical outcomes, complications and cost incurred between two laparoscopic techniques. Only 3 studies comparing TAPP versus IPOM for ventral hernias through minimal invasive technique have been published.<sup>(4)</sup> If a cost effective technique produces same or better results as a commonly done expensive existing technique, then patients from lower socioeconomic strata can also be benefitted.

## METHODS

A retrospective study of patients, who underwent laparoscopic ventral hernia repair over the past one year by a single surgeon (First Author). Institutional Ethics Review Board Clearance was obtained. Patient data of 16 laparoscopic ventral hernia repairs were retrieved. Only elective cases were included. 12 had undergone laparoscopic intra-peritoneal onlay mesh (IPOM) repair, 4 had undergone transabdominal pre-peritoneal repair (TAPP). The basic demographic data (age, gender), co-morbidities, ventral hernia aetiology (primary versus incisional) were recorded. Defect size in cm<sup>2</sup>, whether defect closure was done, the mesh used, the size of the mesh used, and the duration of surgery were collected. The perioperative events like intraoperative complications (haemorrhage, bowel injury), duration of post-operative stay, early complications like surgical site infection, seroma/collection, hematoma; late complications like adhesion, obstruction, enterocutaneous fistula; and recurrence after 24 months follow-up were recorded. The surgical techniques of Laparoscopic IPOM and TAPP was done under general anaesthesia in supine position, three ports were used which included one 10 mm camera port and two 5 mm working ports. In both the procedures the hernia contents were reduced, if required, adhesiolysis was done. The defects were closed with Prolene in all the cases; the suturing was done using intra-corporeal suturing technique. (Figure 1) In IPOM, a composite dual mesh like Parietex™ Composite mesh (Medtronic), Proceed™ Surgical Mesh (Ethicon), with two layers one being non-absorbable and the other being absorbable was used. Parietex™ composite mesh is made from a composite structure of monofilament polyester textile on one side and a hydrophilic absorbable collagen film on the other side.<sup>(5)</sup> Proceed mesh is composed of an inner nonabsorbable PP layer surrounded by polydioxanone on each side. One side of the mesh is covered with a bio-reabsorbable oxidized regenerated cellulose layer that theoretically helps to minimize bowel adhesions, thus preventing many of the complications associated with traditional synthetic mesh.<sup>(6)</sup> Then mesh was placed adequately covering at least 5cm beyond the

defect, fixed with absorbable tackers in a double crown fashion in IPOM (figure 2).

In laparoscopic TAPP, a peritoneal incision was made, and the pre-peritoneal plane was created on all sides of the defect. (figure 3) The sac was dissected from the defect in TAPP and unlike the sac was excised from the defect in IPOM to decrease seroma formation.

Vypro II® Mesh (Ethicon) or PROLENE® Polypropylene Mesh (Ethicon) was used in TAPP. Vypro II® Mesh is made of polypropylene with polyglactin 910. The mesh was placed between the posterior rectus sheath and the peritoneal flap. (figure 3) In TAPP, an additional step of extra-peritonealisation of the mesh was required where the peritoneal flap was closed with vicryl suture/tackers (figure 3). The port sites were closed as routine. The data was analysed using SPSS version 25. The nominal data was presented as frequency, whereas the continuous variables were analysed with the t test for independent samples (for normal distributions) and the Mann–Whitney U test (for non-normal distributions) with a P value of less than 0.05 considered significant.

**RESULTS:** In our study, we had 16 patients of laparoscopic ventral hernia repair during the study period. The demographic details of the participants like age, sex, co-morbidities, type of hernia is given in the table 1. There was no significant difference in the mean hernia defect size, mean mesh size used (table 2). Defects greater than 5cm were excluded in our study. The defect was closed in all the participants. The meshes used among Laparoscopic IPOM cases were Parietex™ Composite mesh in 11, Proceed™ Surgical Mesh in 1 patient; among Laparoscopic TAPP cases, Vypro II® Mesh in 3 and PROLENE® Polypropylene mesh in 1 patient. Table 2 shows there was no significant difference in the intra-operative duration between two groups. Table 3 shows there were no post-operative complications, no recurrence in both the groups. Figure 4 shows the significant difference in mean cost of mesh used in two groups.

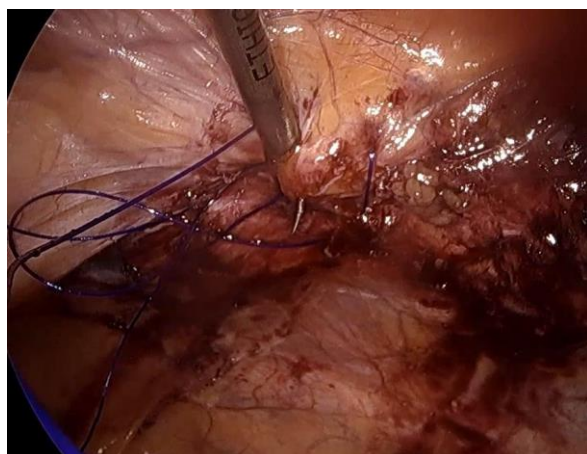


Figure 1: Intra-corporeal closure of the defect.

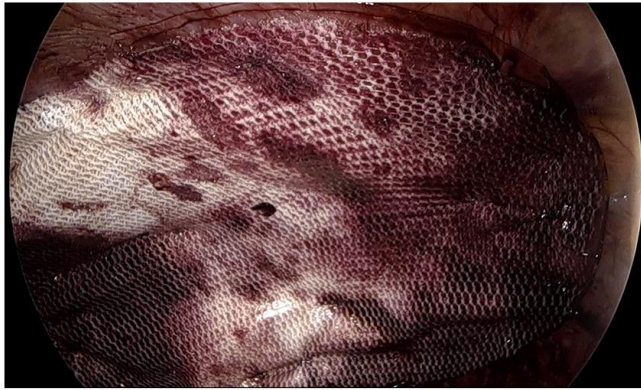
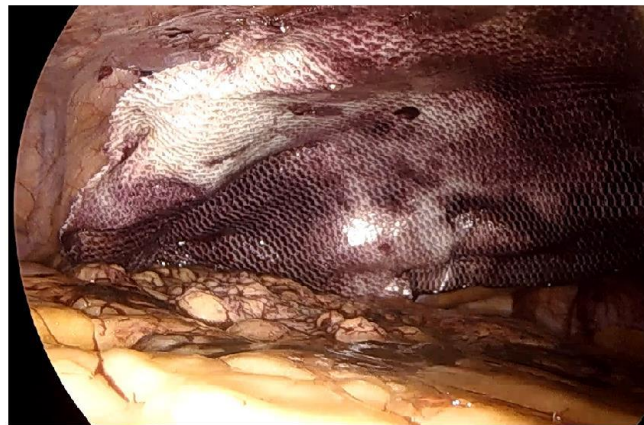

Figure 2:

a. Composite dual mesh fixed to the anterior abdominal wall with tackers,



b. Omentum spread over the viscera to minimise contact between the mesh and the viscera.

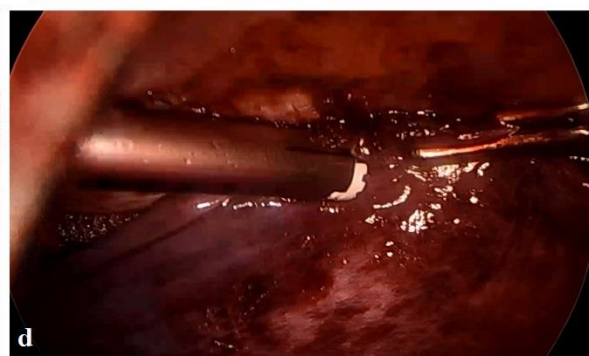
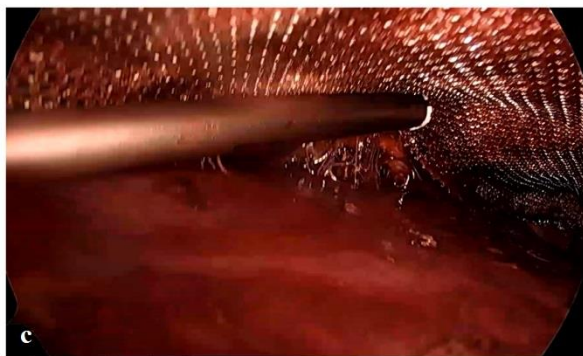


Figure 3:

a,b. The polypropylene mesh between the posterior rectus sheath and the peritoneum;

c. Mesh fixed at few places

d. The peritoneal flap closed and mesh extra-peritonealised.

### MATERIAL COST

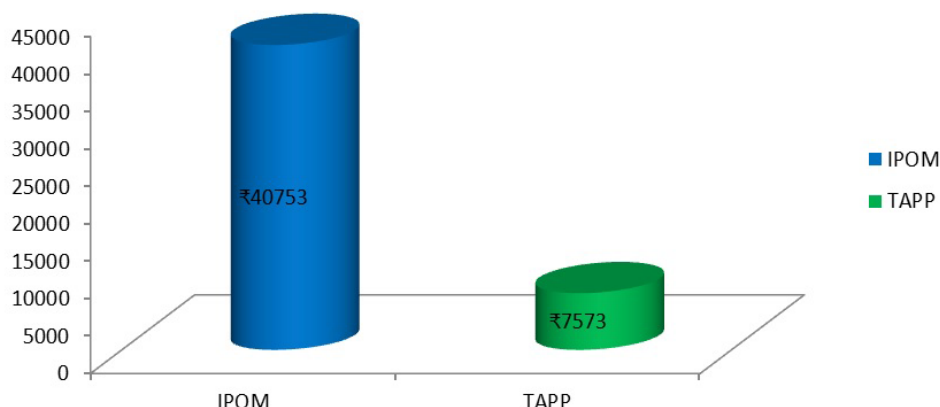


Figure 4: Mean cost of mesh between two groups (40753 INR/ 490 USD versus 7573 INR/ 91 USD, P=0.001).

Table 1:

| Variable              |        | Lap IPOM  | TAPP       |
|-----------------------|--------|-----------|------------|
| Age                   |        | 46.3±10.3 | 45.25±14.6 |
| Sex                   | Male   | 3         | 3          |
|                       | Female | 9         | 1          |
| <b>Co-morbidities</b> |        |           |            |
| Diabetes mellitus     |        | 5         | 1          |
| Hypertension          |        | 4         | 0          |
| Hypothyroid           |        | 2         | 2          |
| <b>Type of Hernia</b> |        |           |            |
| Umbilical             |        | 9         | 4          |
| Incisional            |        | 2         | 0          |
| Both                  |        | 1         | 0          |

Table 2:

| Variable                                 | Lap IPOM     | TAPP       | P value |
|--|--------------|------------|---------|
| Hernia size (cm <sup>2</sup> ) mean ± SD | 4.38±2.28    | 4.78±3.5   | 0.86    |
| Mesh size (cm <sup>2</sup> ) mean ± SD   | 231.25±21.6  | 225±0      | 0.86    |
| Operating time (min) mean ± SD           | 76.25±7.1    | 81.25±8.5  | 0.26    |
| <b>Type of mesh used</b>                 |              |            |         |
| Parietex™ Composite mesh                 | 11           | 0          |         |
| Proceed™ Surgical Mesh                   | 1            | 0          |         |
| Vypro II® Mesh                           | 0            | 3          |         |
| PROLENE® Polypropylene Mesh              | 0            | 1          |         |
| <b>Material costs (₹) mean ± SD</b>      |              |            |         |
| Material costs (₹) mean ± SD             | 40753±3035.2 | 7573±0     | 0.001   |
| Primary defect closure                   | 12           | 4          |         |
| Surgery duration mean ± SD               | 76.25±7.1    | 81.25±8.53 | 0.26    |
| Intraoperative complications             | 0            | 0          |         |

Table 3:

| Postoperative outcomes       | Lap IPOM  | TAPP     | P value |
|------------------------------|-----------|----------|---------|
| Early complications          | 0         | 0        |         |
| Late complications           | 0         | 0        |         |
| Mesh infection               | 0         | 0        |         |
| Postoperative stay mean ± SD | 2.67±0.88 | 2.5±0.57 | 0.77    |
| Recurrence                   | 0         | 0        |         |

## DISCUSSION

The risk factors for ventral hernias are male sex, old age, collagen disorder, and smoking.<sup>(7)</sup> However in our study majority of the patients were women, In our study all the patients had the hernia defects closed with Prolene suture. (Figure 1) Defect closure increases the mesh abdominal wall interface interaction<sup>(2)</sup>, prevents caving in of mesh into the defect, and prevents bulging at the site of repair. Many RCT's have described slightly a higher risk of infection but lower risk of recurrence of hernia with mesh reinforcement. Mesh reinforcement is recommended in clean ventral hernias with high strength & grade of recommendation<sup>(1)</sup> In our study, there was no significant difference in the mean hernia defect size and mesh sizes used between the two groups. IPOM is the simplest laparoscopic ventral hernia technique however with the downsides of increased cost, adhesions, pain. These downsides are circumvented in TAPP by creating a peritoneal pocket where a low cost mesh can be safely placed without being in contact with the intra-abdominal contents.<sup>(8)</sup> TAPP doesn't require extensive fixation as in IPOM, having fewer fixation points may cause less trauma to the nerves and less pain.<sup>(9)</sup> The transfacial suture fixation in IPOM also increases pain in the first 6 weeks.<sup>(10)</sup> Tack fixation in IPOM have been directly related to post-operative pain in many studies.<sup>(11, 12)</sup> We used Vypro mesh in most of our TAPP cases, a light weight mesh with large pore size. Polyglactin added to polypropylene increases it's bending, reduced restriction of abdominal wall mobility and eases intraoperative handling, reduces polypropylene induced inflammation.<sup>(13)</sup> In a study done on rats, there was no difference in adhesion rate between polypropylene and parietex composite mesh.<sup>(14)</sup> So it is safer to use polypropylene, vicryl meshes for TAPP repair, also the extra-peritonealisation decreases any further risk of adhesion formation.

The drawback of TAPP is technical difficulty,<sup>(9)</sup> longer operative time, learning curve, causing rents in the peritoneal flap which needs to be closed. Hence many surgeons prefer IPOM to TAPP which leads to the increased cost of mesh and IPOM not affordable to all patients sometimes forcing patients to opt for open mesh repair. TAPP procedure shows better integration of the mesh with less intra-abdominal lesions, macroscopically the adhesions were less firm in TAPP compared to IPOM.<sup>(15)</sup> Studies have found that polypropylene mesh can be placed in the pre-peritoneal space safely with advantage over an IPOM technique.<sup>(16)</sup> Based on our personal experience, TAPP is a feasible procedure for ventral hernia repair with easy learning curve; hence young surgeons can attempt TAPP under expert supervision in the beginning. Laparoscopic Pre-peritoneal ventral hernia repair through TAPP has minimal morbidity though technically demanding on the surgeon; do not require barrier meshes, with low complication rates.<sup>(17)</sup> The mean cost of mesh in the IPOM group was Indian

Rupees 40753 (490 US Dollars) was significantly higher compared to Indian Rupees 7573 (91 US Dollars) in the TAPP group,  $P=0.001$ . The mesh fixation cost also will be low in the TAPP group owing to minimal fixation tacks used compared to IPOM. This also causes significantly less postoperative pain in the TAPP group compared to IPOM.<sup>(4)</sup> In our study, there was no significant difference in the operative duration and the post-operative stay in the hospital between TAPP & IPOM. One of the criticisms regarding TAPP is it takes more operative time, however in our study there was no significant difference. This operative time difference could be due to the TAPP procedure being technically demanding, making it a procedure for more experienced laparoscopists. In our study, the TAPP procedure was done by an experienced advanced laparoscopic surgeon, there was no significant time consumption for TAPP and there were also no cases of conversion to Laparoscopic IPOM. A surgeon who treats ventral hernia using ventral-TAPP must have undergone in general more laparoscopy training compared to laparoscopic IPOM procedure.<sup>(4)</sup> There were no intraoperative, early, late surgical complications, mesh infection and no recurrence in both the groups on 2 year follow-up. Hence Laparoscopic TAPP is acceptable in terms of outcomes compared with Laparoscopic IPOM with circumventing the drawbacks associated with IPOM. It would be highly benefitting and also affordable for the patients in middle income and poor countries.

## CONCLUSION

Compared to Open surgery, laparoscopic IPOM fares better in terms of fewer infections and wound complications however the pain scores are similar to open surgery<sup>(4)</sup> with mesh in direct contact with the viscera as studies have shown coated mesh don't always prevent adhesion.<sup>(18)</sup> Laparoscopic TAPP fares better than IPOM in circumventing these issues, mesh placed in a separate pocket, less pain, no increase seen in complications or recurrence, with less cost of materials used making laparoscopic ventral hernia repair affordable for the lower socio economic strata people too. Another study concluded that Laparoscopic Extra-peritoneal repair should become the gold standard of ventral hernia repair reporting fewer complications and cost effectiveness.<sup>(19)</sup>

## REFERENCES

1. Holihan JL, Hannon C, Goodenough C, et al. Ventral Hernia Repair: A Meta-Analysis of Randomized Controlled Trials. *Surg Infect (Larchmt)*. 2017;18(6):647-658. doi:10.1089/sur.2017.029
2. Salgaonkar H, Wijerathne S, Lomanto D. Managing complications in laparoscopic ventral hernia. *Ann LaparoscEndoscSurg* 2019;4:11. doi: 10.21037/ales.2019.01.04
3. Mann CD, Luther A, Hart C, Finch JG. Laparoscopic incisional and ventral hernia repair in a district general

- hospital. *Ann R CollSurg Engl.* 2015;97(1):22-26. doi:10.1308/003588414X14055925058913
4. Megas IF, Benzing C, Winter A, et al. A propensity-score matched analysis of ventral-TAPP vs. laparoscopic IPOM for small and mid-sized ventral hernias. Comparison of perioperative data, surgical outcome and cost-effectiveness. *Hernia.* 2022;26(6):1521-1530. doi:10.1007/s10029-022-02586-x
  5. Tandon A, Shahzad K, Pathak S, Oommen CM, Nunes QM, Smart N. Parietex™ Composite mesh versus DynaMesh®-IPOM for laparoscopic incisional and ventral hernia repair: a retrospective cohort study. *Ann R CollSurg Engl.* 2016;98(8):568-573. doi:10.1308/rcsann.2016.0292
  6. Bhanot P, Franklin BR, Patel KM. Proceed™ mesh for laparoscopic ventral hernia repair. *JLS.* 2013;17(4):565-569. doi:10.4293/108680813X13693422519433
  7. Ahonen-Siirtola M, Vironen J, Mäkelä J, Paajanen H. Surgery-related complications of ventral hernia reported to the Finnish Patient Insurance Centre. *Scand J Surg.* 2015;104(2):66-71. doi:10.1177/1457496914534208
  8. Sharma, A., Khan, I., Dewan, A. (2022). TransabdominalPreperitoneal (TAPP) Repair of Ventral Hernia. In: Baig, S.J., Bhandarkar, D., Priya, P. (eds) *Newer Concepts and Procedures in Hernia Surgery - An Atlas.* Springer, Singapore. [https://doi.org/10.1007/978-981-19-5248-7\\_11](https://doi.org/10.1007/978-981-19-5248-7_11)
  9. Shahdhar M, Sharma A. Laparoscopic ventral hernia repair: extraperitoneal repair. *Ann LaparoscEndoscSurg* 2018;3:79. doi: 10.21037/ales.2018.09.07
  10. Beldi G, Wagner M, Bruegger LE, Kurmann A, Candinas D. Mesh shrinkage and pain in laparoscopic ventral hernia repair: a randomized clinical trial comparing suture versus tack mesh fixation. *SurgEndosc.* 2011;25(3):749–755. doi: 10.1007/s00464-010-1246-0.
  11. Brill JB, Turner PL. Long-term outcomes with transfascial sutures versus tacks in laparoscopic ventral hernia repair: a review. *Am Surg.* 2011;77(4):458–465. doi: 10.1177/000313481107700423.
  12. Nguyen SQ, Divino CM, Buch KE, Schnur J, Weber KJ, Katz LB, Reiner MA, Aldoroty RA, Herron DM. Postoperative pain after laparoscopic ventral hernia repair: a prospective comparison of sutures versus tacks. *JLS.* 2008;12(2):113–116
  13. Rosch R, Junge K, Quester R, Klinge U, Klosterhalfen B, Schumpelick V. Vypro II mesh in hernia repair: impact of polyglactin on long-term incorporation in rats. *EurSurg Res.* 2003;35(5):445-450. doi:10.1159/000072230
  14. Biondo-Simões ML, Carvalho LB, Conceição LT, et al. Comparative study of Polypropylene versus Parietex composite®, Vicryl® and Ultrapro® meshes, regarding the formation of intraperitoneal adhesions. *Acta Cir Bras.* 2017;32(2):98-107. doi:10.1590/s0102-865020170202
  15. Díaz-Pizarro Graf JI, Moreno Portillo M, Cárdenas Lailson LE, RamírezSolís ME, Palacios Ruiz JA, ParraguireMartínez S. Laparoscopic transabdominalpreperitoneal approach to place a polypropylene mesh on the abdominal wall: an experimental swine model of a technique that can be used for incisional hernia repair. *SurgEndosc.* 2005;19(7):990-995. doi:10.1007/s00464-003-8291-x
  16. Chowbey PK, Sharma A, Khullar R, Soni V, Baijal M. Laparoscopic ventral hernia repair with extraperitoneal mesh: surgical technique and early results. *SurgLaparoscEndoscPercutan Tech.* 2003;13(2):101-105. doi:10.1097/00129689-200304000-00008
  17. Bittner R, Bingener-Casey J, Dietz U, et al. Guidelines for laparoscopic treatment of ventral and incisional abdominal wall hernias (International Endohernia Society [IEHS])-Part III. *SurgEndosc.* 2014;28(2):380-404. doi:10.1007/s00464-013-3172-4
  18. Sharma A, Chowbey P, Kantharia NS, Baijal M, Soni V, Khullar R. Previously implanted intra-peritoneal mesh increases morbidity during re-laparoscopy: a retrospective, case-matched cohort study. *Hernia J Hernias Abdom Wall Surg.* 2018;22(2):343–351. doi: 10.1007/s10029-017-1686-8.
  19. Ruíz J, Barrios A, Lora A, Vega V, Florez G, Mendivelso F. Extraperitoneal laparoscopic ventral hernia repair: one step beyond. *Hernia.* 2019;23(5):909-914. doi:10.1007/s10029-019-01904-0