

## Original Research

# Autologous Peroneus Longus Versus Hamstring Tendon for Anterior Cruciate Ligament Reconstruction in Knee

<sup>1</sup>Dr. Dinesh Kumar, <sup>2</sup>Dr. Rahul Kunder, <sup>3</sup>Dr. P. K Verma, <sup>4</sup>Dr. P. K Lakhtakia

<sup>1</sup>Assistant Professor, <sup>2,3</sup>Associate Professor, <sup>4</sup>Professor, Department of Orthopedics, Shyam Shah Medical College Rewa, M.P, India

**Corresponding Author**

Dr. Dinesh Kumar

Assistant Professor, Department of Orthopedics, Shyam Shah Medical College Rewa, M.P, India

Email: [oyedinesh@gmail.com](mailto:oyedinesh@gmail.com)

Received: 29 October, 2023

Accepted: 21 December, 2023

**ABSTRACT**

**Background:**An anterior cruciate ligament (ACL) injury is a common knee injury, especially among athletes who participate in sports that involve sudden stops, changes in direction, or jumping. The present study was conducted to assess autologous peroneus longus and hamstring tendon for anterior cruciate ligament reconstruction in knee.

**Materials & Methods:**80 patients with ACL injury of both genders were divided into 2 groups of 40 each. Group I undergoing autologous peroneus longus tendon and group II undergoing hamstrings tendon graft in ACL reconstruction. Both the group of patients were regularly followed up in post-operatively 1 month, 3 months and 6 months and outcomes were measured via IKDC score

**Results:** Group I had 22 males and 18 females and group II had 24 males and 16 females. The right side was involved in 23 in group I and 19 in group II and the left side in 17 in group I and 21 in group II. IKDC score at 1 month was 57.1 in group I, and 58.6 in group II, at 3 months was 66.9 in group I and 67.4 in group II, and at 6 months was 91.2 in group I, and 90.5 in group II. The difference was significant ( $P < 0.05$ ).

**Conclusion:** The donor site morbidity and post-operative knee functional score were similar for both groups.

**Keywords:**anterior cruciate ligament, knee functional score, hamstrings tendon graft

This is an open access journal, and articles are distributed under the terms of the Creative Commons Attribution- Non Commercial-Share Alike 4.0 License, which allows others to remix, tweak, and build upon the work non-commercially, as long as appropriate credit is given and the new creations are licensed under the identical terms.

**INTRODUCTION**

An anterior cruciate ligament (ACL) injury is a common knee injury, especially among athletes who participate in sports that involve sudden stops, changes in direction, or jumping. The ACL is one of the major ligaments in the knee joint, connecting the femur (thigh bone) to the tibia (shinbone).<sup>1</sup>It plays a crucial role in stabilizing the knee joint and preventing excessive forward movement of the tibia relative to the femur. ACL injuries often occur during sports activities when the knee is subjected to sudden twisting, hyperextension, or direct impact. Common causes include landing awkwardly from a jump, sudden changes in direction, or collisions with other players.<sup>2</sup>There are various methods for treating ACL tears. The pre-operative planning for ACL repair heavily depends on the graft selection, however there is still some debate regarding the best graft choice. Several grafts, such as the patellar tendon, quadriceps tendon, hamstring tendon, and other allografts, can be used to repair the ACL. The peroneus longus tendon can be used as an autograft for ACL reconstruction,

but there is a little information regarding clinical outcomes of using this tendon.<sup>3</sup>The strength of a hamstring tendon autograft is comparable to that of a native ACL, and it is simple to harvest and linked with decreased donor site morbidity. One drawback is that it has an unknown graft size and may result in a reduction in hamstring power, which is still important for active young people, especially athletes who need a dominant hamstring power. Additionally, there is a chance of early graft transactions and harm to the sartorial branch of the saphenous nerve during harvesting.<sup>4</sup>The present study was conducted to assess autologous peroneus longus and hamstring tendon for anterior cruciate ligament reconstruction in knee.

**MATERIALS & METHODS**

The present study consisted of 80 patients with ACL injury of both genders. All gave their written consent to participate in the study. Data such as name, age, gender etc. was recorded. Patients were divided into 2 groups of 40 each. Group I undergoing autologous peroneus longus tendon and group II undergoing

hamstrings tendon graft in ACL reconstruction. Both the group of patients were regularly followed up in post-operatively 1 month, 3 months and 6 months and

outcomes were measured via IKDC score. Data thus obtained were subjected to statistical analysis. P value < 0.05 was considered significant.

**RESULTS**

**Table: I Distribution of patients**

Groups	Group I	Group II
Method	autologous peroneus longus tendon	hamstrings tendon graft
M:F	22:18	24:16

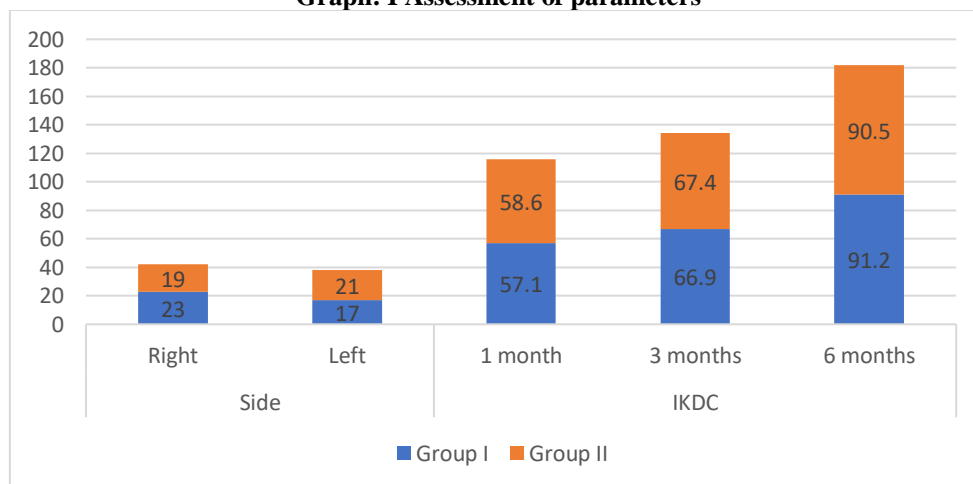
Table I shows that group I had 22 males and 18 females and group II had 24 males and 16 females.

**Table: II Assessment of parameters**

Parameters	Variables	Group I	Group II	P value
Side	Right	23	19	0.91
	Left	17	21	
IKDC	1 month	57.1	58.6	0.04
	3 months	66.9	67.4	
	6 months	91.2	90.5	

Table II shows that the right side was involved in 23 in group I and 19 in group II and the left side in 17 in group I and 21 in group II. IKDC score at 1 month was 57.1 in group I, and 58.6 in group II, at 3 months was 66.9 in group I and 67.4 in group II, and at 6 months was 91.2 in group I, and 90.5 in group II. The difference was significant (P < 0.05).

**Graph: I Assessment of parameters**



**DISCUSSION**

An excellent option is a bone patellar tendon bone autograft because of its ability to promote bone-to-bone healing, which improves tunnel and graft incorporation, and its relatively quick recovery time, which enables a professional athlete to resume sports. It has a quicker recovery time, but there is also a chance of residual flexion contracture, secondary patellar tendonitis, and patellar bone fracture.<sup>5</sup> For double-bundle cases, the patellar tendon graft is not appropriate. In some cases, particularly for individuals with a partial tear or low activity levels, non-surgical approaches such as physical therapy to strengthen the muscles around the knee and wearing a knee brace may be sufficient.<sup>6</sup> For athletes and individuals with significant functional impairment, surgical reconstruction of the ACL may be recommended. During ACL reconstruction surgery, the torn ligament is typically replaced with a graft, often taken from the

patient's hamstring tendon, patellar tendon, or a donor tendon (allograft).<sup>7</sup> The surgery is performed arthroscopically, using small incisions and specialized instruments, to minimize tissue damage and facilitate quicker recovery. Rehabilitation following ACL surgery is a crucial component of recovery. Physical therapy focuses on restoring strength, flexibility, balance, and proprioception in the knee.<sup>8,9</sup> The present study was conducted to assess autologous peroneus longus and hamstring tendon for anterior cruciate ligament reconstruction in knee. We found that group I had 22 males and 18 females and group II had 24 males and 16 females. Singh et al<sup>10</sup> conducted a study on 100 patients who were grouped under two categories. Group A undergoing Autologous Peroneus Longus tendon and Gr B undergoing hamstrings tendon graft in ACL reconstruction. Both group of patients were regularly followed up in post-op week 1, week 4, week 8, and outcomes were measured via

AOFAS score and statistical analysis. Based on our observation we conclude that both the groups were comparable in terms of post-operative knee functional score and donor site morbidity. We found that the right side was involved in 23 in group I and 19 in group II and the left side in 17 in group I and 21 in group II. IKDC score at 1 month was 57.1 in group I, and 58.6 in group II, at 3 months was 66.9 in group I and 67.4 in group II, and at 6 months was 91.2 in group I, and 90.5 in group II. Beynnon et al<sup>11</sup> in their study Twenty-eight received treatment with a two-strand semitendinosus-gracilis autograft, and twenty-eight underwent reconstruction using a bone-patellar tendon-bone autograft. Thirty-nine months was the average follow-up period for the patients (range: thirty-six to fifty-seven months). Twenty-two patients in each group were assessed regarding clinical test results, patient satisfaction, activity level, functional status, and isokinetic muscular strength at the time of the last follow-up. A two-strand semitendinosus-gracilis graft yielded a less favorable objective result than replacing the ruptured anterior cruciate ligament with a bone-patellar tendon-bone graft. When compared to the laxity of the contralateral, normal knee, patients who had undergone hamstring grafting had an average of 4.4 mm more anterior knee laxity at the three-year follow-up interval. In contrast, patients who had undergone bone-patellar tendon-bone grafting had an average of 1.1 mm more laxity in their knees. Of the twenty-two patients who had a hamstring graft, 34% (or three) experienced a mild pivot shift, and 27% (or six) experienced a moderate pivot shift. Of the twenty-two patients who underwent a bone, patellar tendon, and bone transplant, only 14% (three) experienced a slight pivot shift. Patients who underwent a hamstring transplant exhibited notably reduced peak knee-flexion strength in comparison to those who underwent a bone-patellar tendon-bone graft ( $p = 0.039$ ). On the other hand, patient satisfaction, activity level, and knee function (the capacity to run in place, bear weight, squat, climb stairs, and duckwalk) showed comparable results between the two therapies. The limitation of the study is the small sample size.

## CONCLUSION

Authors found that the donor site morbidity and post-operative knee functional score were similar for both groups.

## REFERENCES

1. Bottoni CR, Smith EL, Shaha J, Shaha SS, Raybin SG, Tokish JM, et al. Autograft Versus Allograft Anterior Cruciate Ligament Reconstruction: A Prospective, Randomized Clinical Study with a Minimum 10-Year Follow-up. *Am J Sports Med.* 2015 Oct;43(10):2501-9.
2. Wasserstein D, Sheth U, Cabrera A, Spindler KP. A Systematic Review of Failed Anterior Cruciate Ligament Reconstruction with Autograft Compared with Allograft in Young Patients. *Sports Health.* 2015 May;7(3):207-16.
3. Williams BR, Ellis SJ, Deyer TW, Pavlov H, Deland JT. Reconstruction of the spring ligament using a peroneus longus autograft tendon transfer. *Foot Ankle Int.* 2010 Jul;31(7):567-77.
4. Murawski CD, van Eck CF, Irrgang JJ, Tashman S, Fu FH. Operative treatment of primary anterior cruciate ligament rupture in adults. *J Bone Joint Surg Am.* 2014 Apr 16;96(8):685-94.
5. Sakai H, Yajima H, Kobayashi N, Kanda T, Hiraoka H, Tamai K, et al. Gravity-assisted pivot-shift test for anterior cruciate ligament injury: a new procedure to detect anterolateral rotatory instability of the knee joint. *Knee Surg Sports Traumatol Arthrosc.* 2006 Jan;14(1):2.
6. Xie G, Huangfu X, Zhao J. Prediction of the graft size of 4-stranded semitendinosus tendon and 4-stranded gracilis tendon for anterior cruciate ligament reconstruction: a Chinese Han patient study. *Am J Sports Med.* 2012 May;40(5):1161-6.
7. Ellis SJ, Williams BR, Wagshul AD, Pavlov H, Deland JT. Deltoid ligament reconstruction with peroneus longus autograft in flatfoot deformity. *Foot Ankle Int.* 2010 Sep;31(9):781-9.
8. Sanders TL, Maradit Kremers H, Bryan AJ, Larson DR, Dahm DL, Levy BA, et al. Incidence of Anterior Cruciate Ligament Tears and Reconstruction: A 21-Year Population-Based Study. *Am J Sports Med.* 2016 Jun;44(6):1502-7.
9. Sanders TL, Pareek A, Kremers HM, Bryan AJ, Levy BA, Stuart MJ, et al. Long-term follow-up of isolated ACL tears treated without ligament reconstruction. *Knee Surg Sports Traumatol Arthrosc.* 2017 Feb;25(2):493-500.
10. Anurag Singh, Rohan Krishnan, Jaiveer Singh. Comparative Study of Autologous Peroneus Longus Versus Hamstring Tendon for Anterior Cruciate Ligament Reconstruction in Knee. *International Journal of Innovative Research in Medical Science (IJIRMS).* 2022; 608-610.
11. Beynnon BD, Johnson RJ, Fleming BC, Kannus P, Kaplan M, Samani J, et al. Anterior cruciate ligament replacement: comparison of bone-patellar tendon-bone grafts with two-strand hamstring grafts. A prospective, randomized study. *J Bone Joint Surg Am.* 2002 Sep;84(9):1503-13.