

## ORIGINAL RESEARCH

# Evaluation of Vermian Fossa and Internal Occipital Crest in Adult Human Skulls of Indian Population

Sonali S Vidhale<sup>1</sup>, Rekha M Mane<sup>2</sup>, Kalpesh S Dalvi<sup>3</sup>, Pradeep Bokariya<sup>4</sup>, Charushila D Shinde<sup>5</sup>

<sup>1</sup>Associate Professor, Department of Anatomy, SMBT Institute of Medical Sciences and Research Centre, Igatpuri, Nashik, Maharashtra, India.

<sup>2</sup>Associate Professor, Department of Anatomy, MGM Medical College, Vashi, Navi Mumbai, Maharashtra, India

<sup>3</sup>Associate Professor, Department of Pharmacology, MGM Medical College, Vashi, Navi Mumbai, Maharashtra, India

<sup>4</sup>Associate Professor, Department of Anatomy, Mahatma Gandhi Institute of Medical Sciences, Sevagram, Wardha, Maharashtra, India

<sup>5</sup>Associate Professor, Department of Anatomy, MGM Medical College, Kamothe, Navi Mumbai, Maharashtra, India

### Corresponding Author

Dr. Charushila D Shinde

Associate Professor, Department of Anatomy, MGM Medical College, Kamothe, Navi Mumbai, Maharashtra, India

Email: [charushila29@gmail.com](mailto:charushila29@gmail.com)

Received: 13 October, 2023

Accepted: 09 November, 2023

### ABSTRACT

**Background:** The present study was conducted for assessing the Vermian Fossa and Internal Occipital Crest in Adult Indian Human Skulls. **Materials & Methods:** The study involved assessment of 50 normal dry adult human cranial bases. Exclusion criteria for study included damaged skull and occipital bones. Bones with presence of any form of anatomic and morphologic pathologic lesion were also excluded from the present study. Vermian fossa: Absent/ present, Shape: triangular/quadrangular/atypical and dimensions. Internal occipital crest- Shape: Sharp/ Rounded/ Wide/ ill-defined, Length: Internal occipital protuberance to posterior margin of foramen magnum. All the results were recorded in Microsoft excel sheet and were subjected to statistical analysis using SPSS software. **Results:** Vermian fossa was present in 80 percent of the specimens. Its shape was triangular, quadrangular and atypical in 70 percent, 2 percent and 6 percent of the specimens respectively. Internal occipital crest was sharp and rounded in 54 percent and 40 percent of the specimens respectively while it was wide and ill-defined in 4 percent and 2 percent of the specimens respectively. **Conclusion:** Accurate understanding of the internal occipital crest and Vermian fossa architecture and morphometry, as well as their variations, is crucial for both diagnostic and therapeutic purposes.

**Key words:** Vermian Fossa, Occipital Crest.

This is an open access journal, and articles are distributed under the terms of the Creative Commons Attribution-Non Commercial-Share Alike 4.0 License, which allows others to remix, tweak, and build upon the work non-commercially, as long as appropriate credit is given and the new creations are licensed under the identical terms.

### INTRODUCTION

The vermian fossa (fossa vermiana) is a small midline depression on the internal surface of the squamous part of the occipital bone. It is situated at the inferior end of the internal occipital crest near the foramen magnum. The inferior end of the internal occipital crest bifurcates and gives attachment to falx cerebelli. It is thought that the inferior part of the cerebellar vermis is accommodated between the attached margins of the falx cerebelli, thus the term "vermian fossa."<sup>1-3</sup> The cranial, or inner surface of the occipital bone makes up the base of the posterior cranial fossa. On the squamous part of the inner surface is a midline

vertical ridge called the median internal occipital crest that runs from a median prominence called the internal occipital protuberance to the foramen magnum. The median internal occipital crest provides attachment for the falx cerebri and contains a groove for the occipital sinus.<sup>4,5</sup>

Internal occipital crest and internal occipital protuberance are prominent anatomical landmarks of the floor of the midsagittal plane of posterior cranial cavity. The internal occipital protuberance is identified as an elevated part of cruciform eminence which divides the occipital bone into four fossae: two upper cerebral fossae and two lower cerebellar

fossae.<sup>6,7</sup> Hence; the present study was conducted for assessing the Vermian Fossa and Internal Occipital Crest in Adult Indian Human Skulls.

**MATERIAL AND METHODS**

The present study was conducted for assessing the Vermian Fossa and Internal Occipital Crest in Adult Indian Human Skulls. The study involved assessment of 50 normal dry adult human cranial bases. Exclusion criteria for study included damaged skull and occipital bones. Bones with presence of any form of anatomic and morphologic pathologic lesion were also excluded from the present study. Following parametric variables were evaluated:

Vermian fossa: Absent/ present, Shape: triangular/quadrangular/atypical and dimensions

Internal occipital crest- Shape: Sharp/ Rounded/ Wide/ ill-defined, Length: Internal occipital

protuberance to posterior margin of foramen magnum. All the results were recorded in Microsoft excel sheet and were subjected to statistical analysis using SPSS software.

**RESULTS**

A total of 50 skulls were analyzed. Vermian fossa was present in 80 percent of the specimens. Its shape was triangular, quadrangular and atypical in 70 percent, 2 percent and 6 percent of the specimens respectively. Its height and width were 9.5 mm and 8.1 mm respectively. Internal occipital crest was sharp and rounded in 54 percent and 40 percent of the specimens respectively while it was wide and ill-defined in 4 percent and 2 percent of the specimens respectively. Length of internal occipital crest was 2.94 cm.

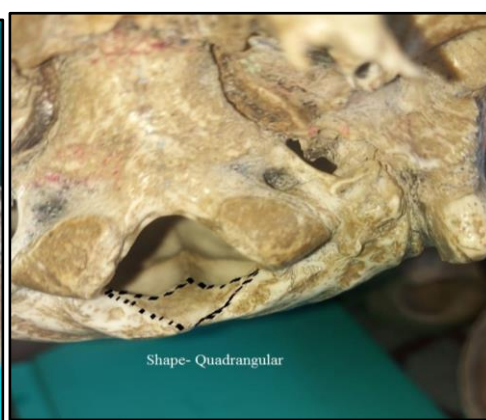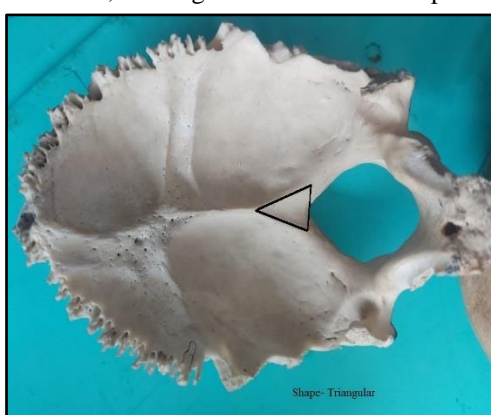


Fig 1: Triangular Shape Vermian Fossa

Fig 2: Quadrangular Shape Vermian Fossa

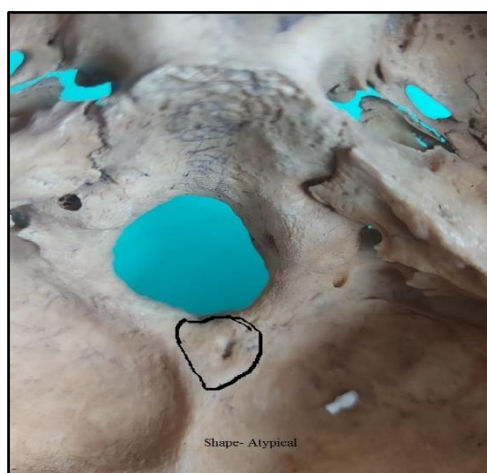


Fig 3: Atypical Shape Vermian Fossa

Table 1: Morphology of Vermian Fossa

Vermian Fossa		Number	Percentage
Occurrence	Absent	10	20
	Present	40	80
Shape	Triangular	35	70
	Quadrangular	1	2
	Atypical	3	6
Height (mm)		9.5	
Width (mm)		8.1	

**Table 2: Morphology of Internal occipital crest**

Internal occipital crest		Number	Percentage
Shape	Sharp	27	54
	Rounded	20	40
	Wide	2	4
	ill-defined	1	2
Length of internal occipital crest		2.94 cm	

## DISCUSSION

In the inner surface of the occipital squama, there is an elevation named the internal occipital protuberance, and from it a prominent median crest, the internal occipital crest, descends to foramen magnum which forms an attachment for the falx cerebelli. Occasionally, the internal occipital crest splits into two to enclose a shallow, triangular depression of variable size, the VF just above the foramen magnum. The inferior vermis of the cerebellum is lodged in the Vermian Fossa.<sup>7-9</sup> Hence; the present study was conducted for assessing the Vermian Fossa and Internal Occipital Crest in Adult Indian Human Skulls.

A total of 50 skulls were analyzed. Vermian fossa was present in 80 percent of the specimens. Its shape was triangular, quadrangular and atypical in 70 percent, 2 percent and 6 percent of the specimens respectively. Its height and width were 9.5 mm and 8.1 mm respectively. In a similar study conducted by Kunc V et al, authors analyzed the prevalence of the VF in 1042 dry skulls. The variable anatomy was classified into either the VF (four categories) or norm. Some rare variations of this region were also encountered. The norm was defined as a flat triangular prominence at the inferior end of the IOC, without any depression. As the most frequent arrangement, the norm appeared in 710 (68.14%) skulls. We observed the fossa in 309 (29.65%), type I in 264 (25.34%), type II in 45 (4.32%) and other rarer variations in 23 (2.21%), skulls, by our new classification system. Despite many different variations can be encountered in the posterior cranial fossa, the proper definition of the usual arrangement at the inferior end of the IOC is still missing.<sup>10</sup>

In the present study, internal occipital crest was sharp and rounded in 54 percent and 40 percent of the specimens respectively while it was wide and ill-defined in 4 percent and 2 percent of the specimens respectively. Length of internal occipital crest was 2.94 cm. Ranjan et al, in a previous study determined the incidence, morphology and morphometry of the vermian fossa in adult human dry skull. Their study was carried out in 110 dry bones, among them 65 were separate occipital bone and 45 were cranial base. All the bones were examined for the existence of a fossa on the inner surface of squamous part of occipital bone, just posterior to the foramen magnum. Height and width of each fossa were measured by a digital vernier caliper. The fossa was macroscopically examined and classified as triangular (type 1), quadrangular (type 2) and atypical (type 3). The fossa

was observed in 88 (80%) bones and its shape was triangular in 62 (70.45%) specimens, quadrangular in 7 (7.95%) specimens and atypical in 19 (21.59%).<sup>11</sup> Archana R et al analysed the morphological, morphometrical and incidence of vermian fossa in 50 dry skulls of South Indian adults. The study was conducted on 50 dry adult human skulls comprising of 32 cranial bases (with vault removed) and 18 occipital bones. The fossae were macroscopically classified as triangular (Type 1), quadrangular (Type 2) and atypical (Type 3). Incidence of VF in the present study was 72%. The VF was identified in 36 skulls, 26 cranial base and 10 occipital bones, and was found absent in the remaining 14 skulls. Type 1 (triangular) VF was present in 29(80.56%) cases and vermian fossa of Type 2 (Quadrangular) was present in four cases (11.11%). Atypical or Type 3 cases were found in three cases (8.33%). The mean length and width of the fossae were  $14.6 \pm 4.1$  mm and  $12.6 \pm 3.1$  mm respectively.<sup>13</sup>

## CONCLUSION

Accurate understanding of the internal occipital crest and Vermian fossa architecture and morphometry, as well as their variations, is crucial for both diagnostic and therapeutic purposes.

## REFERENCES

1. Elze, C., Braus, H., 1954. Anatomie des Menschen, 1st ed. Springer-Verlag, Berlin, pp. 642–643.
2. Tavares, A., 1925. Contribuic, ão oara o estuda da fosseta cerebelosa media (The middle cerebellar fossa). Arq. Anat. Antropol. 9 (2/3), 811–833.
3. Kale, A., Öztürk, A., Aksu, F., Taskara, N., Bayraktar, B., Gürses, I.A., Zebyek, F.G., Özcan, G., 2008. Vermian fossa—an anatomical study. J. Istanbul. Fac. Med. 71, 106–108.
4. Lombroso, G., 1911. Criminal Man. The Knickerbocker press, New York, pp. 4–10.
5. Sarac-Hadzihalilovic A., Dilberovic F. Study on skull asymmetry. Bosnian Journal of Basic Medical Sciences. 2004;4(3):40–46.
6. Watkins K. E., Paus T., Lerch J. P., et al. Structural asymmetries in the human brain: a voxel-based statistical analysis of 142 MIR scans. Cerebral Cortex. 2001;11(9):868–877.
7. Grant JCB and Basmajian JV. Grant's Method of Anatomy. 7th edition. Baltimore: The Williams & Wilkins Co; 1965. p:720- 21.
8. Gray's Anatomy. 39th edition. Spain: Churchill Livingstone. 2005; P: 353-464.

9. Berge JK, Bergman RA. Variations in size and symmetry of the foramina of the human skull. *Clin Anat.* 2001;14(6):406- 13
10. Kunc V, Fabik J, Kubickova B, Kachlik D. Vermian fossa or median occipital fossa revisited: Prevalence and clinical anatomy. *Ann Anat.* 2020;229:151458.
11. Ranjan RK et al. Vermian Fossa: An Anatomical Study of Indian Human Dry Skull. *International Journal of Health.* 2015; 5(8): 235- 242.
12. Archana R et al. Morphology of Vermian Fossa in South Indian Human Adult Skull Bones. *International Journal of Anatomy, Radiology and Surgery.* 2017 Jul, Vol-6(3): AO01-AO04